



Republic of the Philippines
Department of Education
Region VI – Western Visayas
DIVISION OF AKLAN

Arch. Gabriel M. Reyes Street, Kalibo, Aklan



18 October 2017

**To: Chief Education Supervisors
Education Program Supervisors/Coordinators
Public Schools District Supervisors/
Principals/Head Teacher In-Charge of the District
Heads of Division Office Units/Sections
Heads of Public and Private Elementary, Secondary and
Integrated Schools
Others Concerned**

Dear Sirs/Mesdames:


Greetings of Peace!

We sincerely empathize with the medical condition of SARINA C. BALBINO, Teacher III, Angas IS, District of Batan, who needs financial help. She is diagnosed of having pulmonary mass, most probably malignant with bone metastasis, pleural effusion (minimal) to mediastinal lymphadenopathies. Presently, the patient is on chemotherapy at Emmanuel Memorial Hospital in Roxas City.

Your financial assistance will be of great help to alleviate her medical condition. Please channel your financial assistance to Mrs. Feby D. Moleta, Administrative Officer IV (Cash Section), DepED-Division Office, Kalibo, Aklan.

Thank you and God bless your generous heart.

Very truly yours,


Dr. ERNESTO F. SERVILLON, Jr., MNSA, CESO VI
Assistant Schools Division Superintendent
Officer-in-Charge
Office of the Schools Division Superintendent

Unnumbered Division Letter
RMF/mtr



Republic of the Philippines
Department of Education
Region VI – Western Visayas
Division OF AKLAN
Kalibo, Aklan



October 4, 2017

MEDICAL CERTIFICATE

To Whom It May Concern:

This is to certify that Sarina C. Balbino, Teacher III of Angas Integrated School, District of Batan was seen and examined by the undersigned during the regular school visitation.

The patients was referred for further evaluation and was later diagnosed of having, Pulmonary Mass, Most Probably Malignant with Bone Metastasis. Pleural Effusion (Minimal) to Mediastinal Lymphadenopathies.

Presently, the patient is on Chemotherapy at Emmanuel Memorial Hospital in Roxas City.

This certification is issued to Sarina C. Balbino for whatever purpose it may serve her.

A handwritten signature in black ink, appearing to be "Rhoby M. Fernandez", is located above the printed name.

RHOBY M. FERNANDEZ, M. D.
Medical Officer III



Republic of the Philippines
Department of Education
Region VI - Western Visayas
DIVISION OF AKLAN

Arch. Gabriel M. Reyes Street, Kalibo, Aklan



October 4, 2017

To: **Chief Education Supervisors**
Education Program Supervisors/Coordinator
Public Schools District Supervisors/
Principals In-Charge of the District
Senior/Education Program Specialists
Heads of Public and Private Elementary, Secondary and
Integrated Schools

Dear Sirs/ Mesdames:

Greetings of Peace!

We sincerely empathize with the medical condition of Mrs. Sarina C. Balbino, Teacher III of Angas Integrated School, District of Batan, who needs financial help. She is diagnosed of Pulmonary Mass(10x8x8cm) Most Probably Malignant Bone Metastasis Secondary, Pleural Effusion (Minimal) Secondary, S/P CT Biopsy, Post Obstruction Pneumonia.

Your voluntary financial assistance will be of great help to alleviate her medical expenses. Please channel your financial assistance to Mrs. Feby D. Molleta, Administrative Officer IV (Cash Section), DepED-Division Office, Kalibo, Aklan

Thank you and God Bless your generous heart.

Very truly yours

MR. MICHAEL T. RAPIZ
Chief Education Supervisor
Schools Governance and Operation Division

Unnumbered Division Letter
RMF/bsm

“ May katawhayan ag kalipayan sa among mga eskuelahan ”

PANAY HEALTH CARE

MULTI-PURPOSE COOPERATIVE

CDA Reg. No. 9520-06000853

HOSPITAL

PANAY HEALTH CARE MULTI-PURPOSE COOPERATIVE HOSPITAL
Estancia, Kalibo, Aklan

MEDICAL CERTIFICATE

September 7, 2017

Date

TO WHOM IT MAY CONCERN:

This is to certify that SARINA BALBINO of

Angas Batan, Aklan

confined in this hospital on/from September 5, 2017 to September 7, 2017
(Date Admitted) (Date Discharged)

with the following findings and/ or diagnosis:

PULMONARY MASS (10 x 8 x 8 CM) MOST PROBABLY MALIGNANT
BONE METASTASIS SECONDARY

PLEURAL EFFUSION (MINIMAL) SECONDARY

MEDIASTINAL LYMPHADENOPATHIES SECONDARY

S/P CT BIOPSY, POST OBSTRUCTION PNEUMONIA

and would need recuperation for _____ days barring complication.

PATRICK DEXTER BUENAFLOR M.D., FPCP

Attending Physician

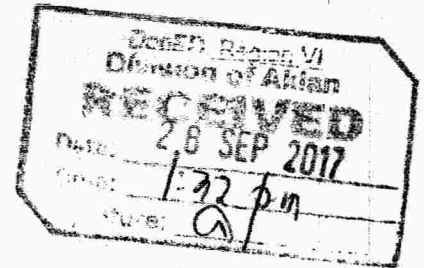
Paulyn V. Jarina-Zonita, MD
Lic. # 0235635

LIC. No: 108838

PTR No: 6156589

(NOT VALID WITHOUT SEAL)

Department of Education
Region VI – Western Visayas
Division of Aklan
District of Batan



September 28, 2017

Dr. ERNESTO F. SERVILLON JR., MNSA, CESO VI
OIC – Office of the Schools Division Superintendent
Division of Aklan

Sir:

Greetings of Peace and Love!

The undersigned appeal to your office for a benevolent assistance in the Division of Aklan for the medication of **Mrs. Sarina C. Balbino**, Teacher III of Angas Integrated School, this District, who is suffering from **Pulmonary Mass** and **Bone Metastasis**.

Hoping that this request be given favorable action for the best interest of the service.

May our Almighty One return his blessings to you a hundredfold.

Very truly yours,

EVAN C. REGALADO

SP – I/ Principal In – charge of the District



THE HEALTH CENTRUM, INC.

Teodorica Avenue, Banca, Roxas City
Email: thehealthcentrum@gmail.com

MEDICAL CERTIFICATE

This is to certify that **SARINA C. BALBINO, 50 YEARS OLD, FEMALE, MARRIED, FILIPINO** and a resident of **ANGAS, BATAN, AKLAN** admitted **SEPTEMBER 27, 2017** and discharged on **OCTOBER 02, 2017**.


Medical Diagnosis:

**SPONTANEOUS BACTERIAL PERITONITIS SECONDARY TO
ASCITES OF MALIGNANCY
ADENOCARCINOMA OF LUNGS STAGE IV
HYPERTENSIVE CARDIOVASCULAR DISEASE**

Procedure/Operation:


NONE

Remarks:


DR. MITZI BANATE/ DR. ANTONIO VIRAY, III
Attending Physician/ Hospital House Physician
License Number: **064456**

Prepared by:


VERONICA M. SAYO
Medical Records Officer



Note: This certificate is issued upon the request of (THE PATIENT) for whatever official purpose it may serve best and not valid for medico- legal/court use.

Given this **05th** day of **OCTOBER, 2017**.

*Not Valid
Without Seal*



THE HEALTH CENTRUM, INC.

Teodorina Avenue, Bantay, Roxas City
Email: thehealthcentrum@gmail.com

MEDICAL ABSTRACT

Name: Sarina Balbino
Age: 50
Sex: Female
Civil Status: Married
Address: Batan, Aklan

Hospital No.: 2017-008821
Room: 215
Date Admitted: 09/11/2017
Date Discharged: 09/13/2017
Attending Physician/s: Dr. Miltzi Banate

Chief complaints: Body Malaise

History of Present Illness:

5 months PTA, patient noted recurrent low back pain.


3 months PTA, patient was diagnosed to have a pulmonary mass.

1 week PTA, biopsy of the pulmonary mass was done.

On the day of admission, persistence of signs and symptoms prompted patient to seek admission.

Physical Findings at time of Admission:

- Awake, conscious, not in CP distress
- Anicteric sclerae, pink palpebral conjunctivae,
- Symmetrical chest expansion, CBS
- Adynamic precordium, NRRR
- Flat, soft, NABS
- Grossly normal extremities, (-)edema



VERONICA M. SAYO
Medical Records Officer

Course in the Wards:

On the day of admission, patient was seen, examined and medications started. Patient was referred to Anesthesia and Ortho service. Patient was followed up and noted improvement. Patient was eventually discharged.

Pertinent Laboratory Findings:

UTZ – Whole Abdomen :

9-11-17 Fatty Liver ; Non-Obstructing Nephrolithiasis, Right

UTZ – Chest :

9-14-17 Minimal loculated pleural effusion, Right

Complete Blood Count:

Date	Hgb	Hct	RBC	WBC	Seg	Lympho	Plt ct
9-11-17	14.1	0.43	4.76	15.8	82	13	adequate
9-18-17	11.3	0.34	3.88	12.4	86	10	adequate

Blood Chemistry

	9-11-17
Uric Acid	394
SGPT	18
Sodium	137.5
Alk phos	307
Creatinine	41
Calcium	2.52

CXR :

9-12-17 : No pulmonary infection; Consider Liver pathology; No pulmonary congestion

Medications:

1. Calvit Plus tab OD
2. Sambong Releaf 2 tabs BID
3. Clarithromycin 500 mg tab BID
4. Cefixime 200 mg tab BID
5. Symbicort, 2 puffs BID
6. Amlodipine 5 mg tab OD
7. Polynerve tab OD
8. Pregabalin 150 mg tab Q6
9. Tramadol 100 mg tab Q8

Final Diagnosis:

Pneumonia – High Risk with Hypoxemia
Adenocarcinoma of the Lungs stage II
HCVD

